

CASE REPORT

AN APPROACH TO FISH-HOOK INJURY IN CHILDREN IN REMOTE HOSPITAL: A CASE REPORT AND BRIEF LITERATURE REVIEW

Suryaman Menyangbo^{1*}, Harihar Devkota¹

¹ Department of General Surgery, Karnali Academy of Health Sciences, Jumla, Nepal

**Correspondence to:* Dr. Suryaman Menyangbo, Department of General Surgery, Karnali Academy of Health Sciences, Jumla, Nepal.
Email: Suryaman2034@gmail.com

ABSTRACT

Background: Fish-hook injury is a leisure activity based for many across the globe among adults. Sometimes, it has been occasionally happened in the playing group children when the fishing rod with hook kept carelessly and children try to play and caught hand or bodily injury. If the hook is snug then it becomes difficult to removal. We report two cases of such injury in the hand and discuss the technique for its removal with a short literature review. Cases: A 3 year and 15 years old male accidentally suffered a fishhook into their great thumb. They came to the surgical OPD one day and same day respectively after the incident with pain. Unsuccessful attempts at removal were made. A retrograde pull method was applied to remove fish hooks successfully. Conclusion: Fish-hooks can be removed in children less traumatically following same technique for adult with a proper wound and pain care.

Key words: Fishhook injuries, Pediatrics, Remote hospital.

INTRODUCTION

Fish-hook injury is a leisure activity based for many across the globe. But, it has been occasionally seen in the playing children when the fishing rod kept carelessly and children try to play and caught hand injury. Hook, the front end is barbed so that it gets caught into the fish's mouth, commonly involves the hand injury. The external injury seems minimal but, the internal injuries can be dangerous particularly when it is near to a vessel, tendon or nerve. Patients are often tried by their relatives to remove it forcefully and cause more tissues damage and inappropriate wound care.

CASE REPORT

A 3 years male and 15 years male children accidentally suffered a fishhook into their great thumb while playing. They came to the surgical OPD one day after the incident with pain in and a fish hook hanging on right great thumb (Figure 1). Bleeding from the entry site was mild as well as mild swelling of the pulp. Unsuccessful attempts at removal were made

by their relatives in the village. Proper asepsis was ensured; then local anaesthesia was administered using 4% lignocaine spray and waited for five minutes. Since the hook was embedded not deep into the muscle, it was removed simply by retrograde pull method. Thorough cleaning of wound with normal saline and betadine was performed. The patient was sent home with analgesics.

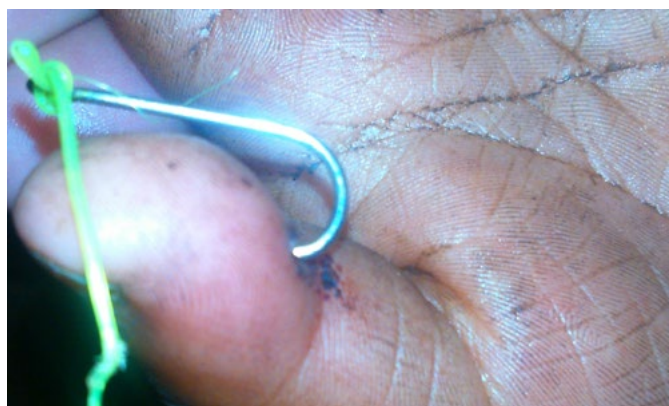

Figure 1: Fish hook injury in right great thumb




Figure 2: Removed barbed fish hook

DISCUSSION

Fishing can, at times, be a dangerous event for fisherman and fishing hobby people which is not that unusual. But it can also lead to an accident to the children, however, it is rare, due to the careless of keeping fishing rod and string with barbed hook. This is not surprising when the most important piece of the fishing gear is a sharp curved metal hook. The potential dangers of a fish hook have been explained recently¹. The hand is most commonly injured followed by the head and eyes. Although the former injury can be managed in the emergency department, the latter needs specialized care². If one is not familiar with fishing gear, injury becomes more probable. With more modifications in the hook design, the emphasis is mostly on the barbed end. It is designed to snag the fish’s mouth and makes hook removal difficult. However, it was not modified hook in our two cases. No guideline is presently available in the literature for safe removal of fishhook for child to the best of our knowledge. Proposed techniques are as follows (Figure 3-4);

1. Retrograde technique
2. String pull technique
3. Needle cover technique
4. Advance and cut technique

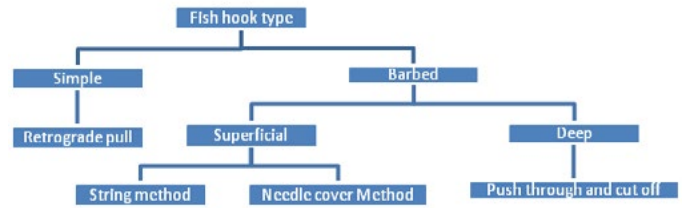


Figure 3: Fish Hook removal method based on the type of Hook and injuries

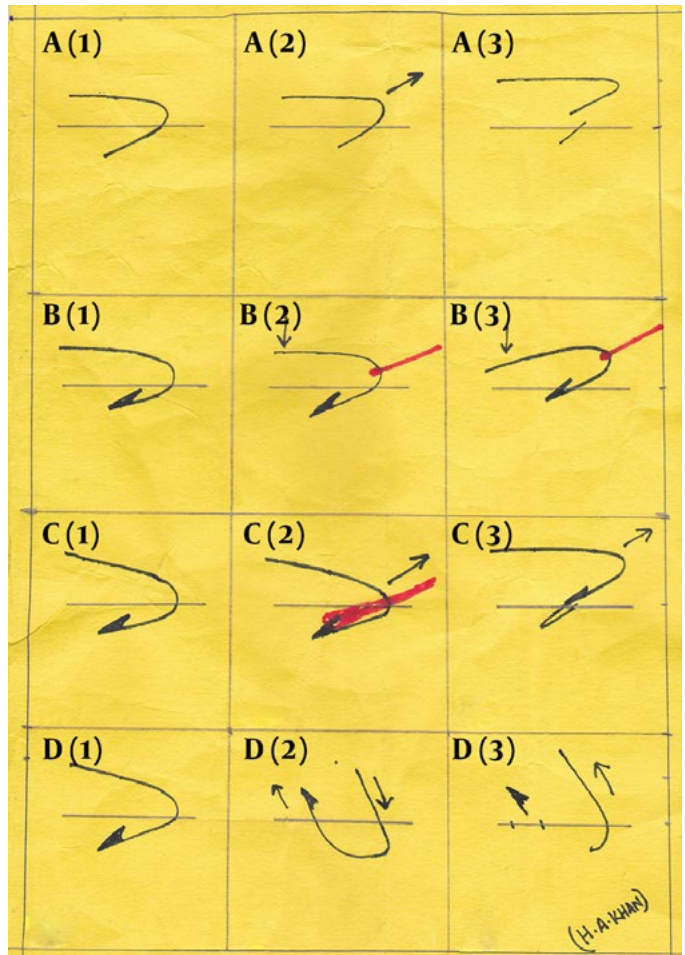


Figure 4: Technique of hook removal

A1-3: retrograde pull method; B1-3: string pull method, red line show the string;

C1-3: Needle cover technique, red line indicates the needle cover;

D1-3: push through and cut off

There are very few literatures found regarding the fish hook injury and management in children.

Some of the literatures for adult fish hook injury and management are explained by Doser et al.³ in a study on 100 patients found the retrograde technique useful in only 40 patients. The string pull technique is the modified retrograde technique with the advantage of being less traumatic to soft tissues, and does not need another exit site. Cooke⁴ described how to remove fish hook with a string which has undergone lot of modifications till now. However, its effectiveness on deeply embedded barbed hooks is questionable. Furthermore, in areas where the risk of damage to vascular structures is greater, this technique cannot be applied. The needle cover technique can be effectively applied for superficially embedded barbed fishhooks. Being a blind procedure, its use for deeply embedded hooks in high risk neurovascular areas cannot be guaranteed. Prats et al. emphasized the management of injuries caused by barbed hooks but showed his method on only two cases⁴. Nabi et al. discouraged home removal of fish hooks by unqualified persons in a single case report. However in their technique the barb was not cut as it was easily disengaged by slight rotation which was possible in the first web space of the hand⁵. The retrograde pulling method is used successfully all types of barbed hooks⁴. The hook is pulled back through and the barbed end is pulled under direct vision, thus minimizing injury to soft tissue or the underlying structures. Since the patients had come to OPD from a far distance, it had been decided to remove hook the same day in minor operation under spray local anesthesia. It was found that the effectiveness of spray anesthesia especially in children who were afraid to injection was good and quite comfortable. Whatever technique is used, wound care is of utmost importance. Thorough washing with aseptic and proper tetanus prophylaxis for unimmunized patients (we had given tetanus prophylaxis to the one who is 15 year old) are the basic requirements of wound care. Though use of antibiotics is not recommended for superficial wounds², however, prophylactic oral fluoroquinolones to cover *Aeromonas hydrophila* are recommended for deep wounds^{6,7}. Patients should be followed for proper healing and absence of infection. Semel et al.⁸ in their study warned regarding rapidly progressive nature of soft tissue infections in water-associated traumatic wounds; 39% of their cases had associated fascia, muscle, tendon, bone or joint infections. Thorough lavage,

atraumatic removal and prophylactic antibiotics decrease the risk of infection. Since the injury in our cases was an accident happened in home on and the wound was superficial, the prophylactic antibiotic was not recommended, rather the good analgesic with.

ACKNOWLEDGEMENT

Dr Suryaman Menyangbo; Dr Harihar Devkota; Dr susma Subba

REFERENCES

- [1] Inchingolo F, Tatullo M, Abenavoli FM, Inchingolo AD, Inchingolo AM, Dipalma G. Fish-hook injuries: a risk for fishermen. *Head & Face Medicine* 2010; 6(1):28.
- [2] Danesh J, Donnoghue M, Dixon G. Fish-hook injuries-wounded anglers and string theory, *NZ Med J* 1992;105(931):136.
- [3] Cooke T. How to remove fish –hooks with a bit of string. *Med J Aust* 1961; 48(1):815-6.
- [4] Prats M, O'Connell M, Wellock A, Kman NE. Fishhook removal: case reports and a review of the literature. *J Emerg Med* 2013;44(6):e375-80.
- [5] Nabi DG, Tak SR, Mir MR, Halwai MA, Kangoo KA, Kawoosa AA. Fish Hook Injury of hand :Should Home Removal be Attempted? *Inter J orthop Surg* 2008; 9(1).
- [6] Haburck DR. *Aeromonas hydrophilla*: Unappreciated danger to fishermen. *Medscape CME. Infect Med* 1996;13(10):893-6.
- [7] Archer BJ, Holm RP. Treatment of *Aeromonas hydrophilla* infection in a deep tissue wounds. *SD J Med.*1995;48(12):405-7.
- [8] Semel JD, Trenholme G. *Aeromonas hydrophila* water-associated traumatic wound infections: a review. *J Trauma* 1990;30(3): 324-7.