



## ORIGINAL RESEARCH ARTICLE

### A STUDY OF KAPANDJI INTRAFOCAL PINNING FOR THE TREATMENT OF UNSTABLE EXTRA-ARTICULAR DISTAL RADIUS FRACTURES

Tirthendra Khadka<sup>1</sup>, Rudra Prasad Marasini<sup>1\*</sup>, Dirgha Raj RC<sup>1</sup>, Rojan Tamrakar<sup>1</sup>, Prakash Bahadur Thapa<sup>1</sup>, Yagya Raj Kharel<sup>1</sup>, Gyanendra Shah<sup>1</sup>

<sup>1</sup>Department of Orthopedics and Trauma, National Academy of Medical Sciences (NAMS), Kathmandu, Nepal.

\*Correspondence to: Dr. Rudra Prasad Marasini, Department of Orthopedics, Bharatpur Hospital, Chitwan, Nepal. Email: [drmarasinirp@gmail.com](mailto:drmarasinirp@gmail.com)

#### ABSTRACT

Intrafocal pinning of distal radius fracture is indicated in unstable distal radius fractures without significant intra-articular displacement. It is a simple and effective, minimally invasive method of fixation for achievement of alignment and stability of unstable fractures. The study was conducted between November 2013 and October 2016. Patients attending the emergency and outpatient departments with history of trauma followed by pain and swelling of wrist, were evaluated clinically & radiologically. Patients with distal radius fracture who met the criteria were enrolled in the study. The operation was performed either under regional anaesthesia or intra venous anaesthesia. Reduction was carried out under image intensifier guidance and intrafocal pinning was undertaken with 2 Kirschner wires as described by Kapandji. Above elbow slab was applied for 3 weeks. Kirschner wires were removed at 6th week. Follow ups were done with radiological and functional evaluation on 1st week, 3rd week, 6th week, 12th week and 6 month. Of the 30 cases enrolled in our study, the age ranged from 40 to 72 years and the mean age of the patients was 54.77 years. The female/male ratio was 5:1 and the majority (83%) of patient sustained injury due to trivial trauma. All fractures united by 6 weeks. In the final follow up at 6th month, assessment of range of motion showed almost full range of motion. Functional evaluation was carried out with Gartland & Werleys Demerit point system (modified by Sarmiento et al). According to the score, 9 patients had excellent, 19 had well and 2 had fair results. None of the patient had poor results. Kapandji intrafocal pinning provides a stable fixation and good functional outcome in extraarticular distal radius fractures with few complications only.

**Key words:** Distal radius, Kapandji, Intrafocal.

#### INTRODUCTION

The distal radius fractures are the most common of the upper extremity fractures representing 17% of all fractures treated each year.<sup>1,2</sup> Although distal radius fractures are most common among the females over 40 years of age, young adults make up a significant portion of the cases. Treatment of displaced distal radius fractures has changed over the period of time. In the past, closed reduction with cast immobilization was considered the treatment of choice. However, these methods often results in unsatisfactory anatomical and functional outcomes with varying degree of deformity and disability. To address these problems, Kapandji<sup>3</sup> mentioned a method of Kirschner wire (K-wire) osteosynthesis in which the wires were inserted from the dorsal

aspect “intrafocally” i.e. into the fracture gap with good results. The purpose of this study was to assess the outcome of distal radius fractures among adults treated with Kapandji technique.

#### MATERIAL AND METHODES

This is a prospective observational study conducted at National Academy of Medical Sciences, Kathmandu during the period of 3 years (November 2013 to October 2016). Total 30 patients of both sexes of age groups 30 to 75 years with extra-articular distal radius fractures (Frykman type I & II) were included in the study. Patients with intra-articular fractures, marked dorsal radial comminution, ipsilateral upper

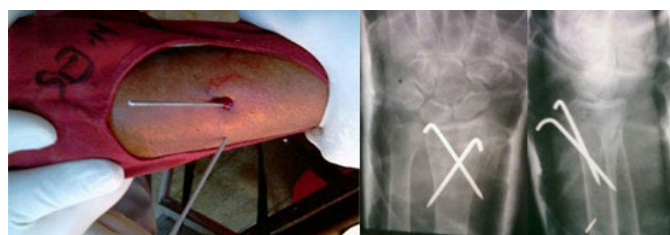
extremity fractures, open fractures and polytrauma patients were excluded. The approval for the study was obtained from the institutional review board. Patients with distal radius fracture who met the criteria were enrolled in the study. Informed consent was taken.

**Surgical procedure (Kapandji technique)**

Patient was positioned supine in operation table and preoperative prophylactic intravenous antibiotic (Cefazolin 1 gm) was given. All the patients were operated either under brachial block or general anaesthesia. Reduction was performed with traction and counter-traction under image intensifier guidance. After maintaining aseptic precautions, a stab incision was made and a K-wire mounted in a drill sleeve was inserted directly into the fracture gap, initially directed at 90 degrees. The wire was inserted directly at the proximal, dorsal margin of the fracture to support area of comminution. The fracture was aligned, drill sleeve was connected to the drill and the K-wire was anchored at an angle of 45 degrees in the opposite cortex. The manoeuvre was repeated for the lateral part of the fracture gap with second K-wire. The bending and cutting of the K-wires were just above the skin. Above elbow cast was applied. The patients who received brachial block were observed for 4 hours, postoperative check X-ray was taken. Possible complications and precautions were explained. The patient was evaluated next day in OPD for possible complications and was call for first follow up after 1 week. The patients who underwent procedure under general anaesthesia were admitted in postoperative ward for a day. They

were discharged on first post-operative day following the check X-rays. They were also called after 1 week & precautions were explained. All patient received analgesics for 3 days and no patients received post-operative antibiotics.

All the patients were followed up at 1<sup>st</sup>, 3<sup>rd</sup>, 6<sup>th</sup>, 12<sup>th</sup> and 24<sup>th</sup> weeks. On every follow up, all the patients were evaluated clinically for the features of clinical union and appearance of any complications of the procedure. Radiological evaluations were done at the immediate post-operative period and at 6th week follow up. At the third week follow up, above elbow cast was shortened to below elbow with initiation of elbow range of motion exercise to prevent elbow stiffness. K-wires were removed at 6<sup>th</sup> week. Physiotherapy & mobilization was started after removal of cast. For radiological evaluation, we assessed the radial inclination; radial height, ulnar variance and volar tilt at the final follow up and compared with the average measurements provided in the standard orthopaedic textbook. The functional evaluation was done at the final follow up by using Demerit point system of Gartland and Werley’s with Sarmiento et al. modification



**Figure 1: Surgical procedure and radiographs showing the Kapandji technique.**

**Functional Evaluation**

**Table 1: Gartland & Werley Demerit point system modified by Sarmiento et al.**

Residual deformity	Points	Subjective evaluation	Points
Prominent ulnar styloid	1	Excellent – no pain, disability, or limitation of motion	0
Residual dorsal tilt	2	Good – occasional pain, slight limitation of motion, no disability	2
Radial deviation of hand	2–3	Fair – occasional pain, some limitation of motion, feeling of weakness in wrist, no particular disability if careful, activities slightly restricted	4
		Poor – pain, limitation of motion, disability, activities more or less markedly restricted	6
Point range	0–3	Point range	0-6

**Table 2: Objective evaluation and complications.**

Objective evaluation	Points	Complications	Points
Loss of dorsiflexion	5	Arthritic changes	
Loss of ulnar deviation	3	Minimum	1
Loss of supination	2	Minimum with pain	3
Loss of palmar flexion	1	Moderate	2
Loss of radial deviation	1	Moderate with pain	4
Loss of circumduction	1	Severe	3
Loss of pronation	2	Severe with pain	5
Pain in distal radioulnar joint	1	Nerve complications (Median)	1-3
Grip strength - 60% or less of opposite side	1	Poor finger functions due to cast	1-2
Point range	0–5	Point range	0-5

**Table 3: End results of the evaluation.**

Excellent	0-2
Good	3-8
Fair	9-20
Poor	21 and above

**Data analysis:**

The selected data was analysed with the help of SPSS (Statistical package for social science) windows program 16.5 version. The student t-test quantitative variables were used and values of P= <0.05 were considered significant with confidence level of 95% throughout the study.

**RESULTS**

The mean age was 54.77 years. There were 24 female patients (80%) and 6 male patients (20%). Nineteen patients (63.33%) had fractures involving left wrist and remaining 11 patients (36.66%) had fractures on the right wrist. Seventy (21 cases) fractures were classified as Frykman’s type I and 30% (9 cases) as Frykman’s type II. The mode of injury in 25 patients (83%) was trivial fall, in 4 patients (13%) was road traffic accident and 1(4%) patient suffered injury due to domestic violence. Clinical and radiological signs of union were noted in 2<sup>nd</sup> follow up onwards. In 7 fractures (23%), sign of union was observed at 3<sup>rd</sup> week and all 30 fractures (100%) united by 6<sup>th</sup> week.

**Range of motion**

The range of motion (dorsiflexion, palmarflexion, supination, pronation, radial deviation and ulnar deviation) was assessed at 6<sup>th</sup> week, 12<sup>th</sup> week and 24<sup>th</sup> week. The mean wrist dorsiflexion at final follow up was 48.17 degrees (p-value 0.639), palmarflexion 56.17 degrees (p value 1), supination 75.37 degrees (p value 0.165), pronation 77.6 degrees (p value 0.876), radial deviation 13.40 degrees (p value 0.221) and ulnar deviation 32.2 degrees (p value 0.849). The range of motion was comparable with opposite wrist.

**Radiological Assessment**

At final follow up at 24<sup>th</sup> week, radial height was 9.23mm (p value 0.467), radial inclination 21.33 (p value 0.941) and volar tilt was 6.37 (p value 0.126).

Functional result according to Gartland and Demerit Point System

Functional evaluation was done according to Gartland and Werley’s Demerit Point System

(modified by Sarmiento et al). At final follow up, 9 patients had excellent, 19 had good and 2 had fair results. Hence, 93.33% patient had either excellent or good results.

## DISCUSSION

Intrafocal pinning of distal radius fractures was described first by Kapandji<sup>3</sup> in 1976. It is indicated in unstable distal radius fractures without significant intra-articular displacement. It provides the surgeon with a simple and effective, minimally invasive method of improving alignment and stability of unstable fractures<sup>4</sup>. We had female predominance of above 40 years of age among 30 patients, which was quite similar to the studies shown by P.C. Strohm et al<sup>5</sup>, Dowry Paul A. et al<sup>6</sup> and Ruschel et al<sup>7</sup>. Female predominance may be due to their activity level at household as well as outdoor activities like agriculture in our context. Further, their bone was osteoporotic because of nutritional factors and physiological factors like menopause, which increased the risk of fracture with trivial trauma.

Dowry Paul A. et al<sup>6</sup> recommended that intrafocal pinning should be added to the surgical armamentarium in treating distal radius fractures. In their study, there was a trend for patients with osteopenic bone to lose their postoperative reduction. Majority of their patients were happy with the surgery and the outcome of their wrists. In our case series, using Gartland and Werley Demerit point system (modified by Sarmiento et al), 9 patients (30%) had excellent, 19 patients (63%) had good and 2 patients (7%) had fair results. None of the patients had poor results. Similarly, Ruschel et al<sup>7</sup> concluded that Kapandji's intrafocal fixation technique showed to be effective for the treatment of unstable, extra-articular distal radius fractures, with easy learning curve and performance. According to the Gartland and Werley method, they showed 72.1% excellent and good results after three months; 89.7% after six months; and 96.6% after 12 months.

We observed complications only in 3 patients. Those were 2 cases of pin tract infection which resolved after one week of antibiotics and regular dressing and one case of reflex sympathetic dystrophy which eventually improved. P.C. Strohm et al<sup>5</sup> observed complications in 17% of cases in their study. The noted complications were nerve irritation, swelling,

wire migration, reflex sympathetic dystrophy and carpal tunnel syndrome. All complications resolved at final follow up. Ruschel et al<sup>7</sup> mentioned that there were 4 cases (13.7%) of reflex sympathetic dystrophy, one case of pin tract infection and one case of radial sensory branch irritation. However, all the complications were recovered by follow up at 6<sup>th</sup> month. Out of 17 fractures included in the study of Dowry Paul A. et al<sup>6</sup>, complications were noted in 3 cases. They were extensor tendon rupture in one patient, pin tract infection in one patient and loss of reduction requiring reoperation in one case. All the complications were manageable and eventually resolved. However, we noted comparatively lower frequency of complications in our study that might be because we had younger patients (mean age 54.77 years) and with shorter follow up period (6 months) as compared to the other studies.

So, various studies<sup>4-16</sup> showed superior functional outcome with Kapandji intrafocal pinning for unstable extra-articular distal radius fractures among adults. Although we had found good to excellent functional outcome with this technique, there are some limitations of this study. First, we included few numbers of patients in this case series, so large number of patients must be included to further validate the results. Second, we compared the radiological parameters with the standard average measurements provided in the standard textbooks, which might not be the same for our population. Third, we did not do comparison this technique with other available procedures, so that we could claim this procedure as a superior one.

## CONCLUSION

Kapandji intrafocal pinning is safe, simple and easy procedure for unstable distal radius extraarticular fractures that provide good to excellent radiological and functional outcomes with very few complications.

## REFERENCES

1. Brinker MR. Review of Orthopaedic Trauma. Philadelphia:W.B. Saunders Company;2001. page 277 – 284.
2. Bucholz RW, Heckman JD, Court-Brown CM. Rockwood and Greens Fractures in adults. 6<sup>th</sup> ed. Lippincott Williams and Wilkins;2006. page 910 -961

3. Kapandji A. Intra-focal pinning of fractures of the distal end of the radius 10 years later. *Ann Chir Main.* 1987; 6:57-63.
4. Hughston JD: Fracture of the distal radial shaft, mistakes in management. *J Bone Joint Surg.* 1957,39A:177-181
5. Strohm PC, Müller CA, Boll Tand, Pfister U. Two Procedures for Kirschner wire osteosynthesis of distal radial fractures a randomized controlled trial. *J Bone Joint Surg Am.* 2004; 86:2621-2628.
6. Dowdy PA, Patterson SD, King GJ, Roth JH, and Chess D. Intrafocal (Kapandji) Pinning of unstable distal radius fractures: A preliminary report. *The Journal of Trauma: Injury, Infection, and Critical Care.* 1996;40(2):194-198
7. Ruschel PH, Albertoni WM. Treatment of unstable extra-articular distal radius fractures by modified intrafocal Kapandji method. *Techniques in hand and upper extremity surgery.* 2005;9(1):7-16
8. Parikh SN, Divatia PA, Parikh PN. Intrafocal (Kapandji) pinning of unstable distal radius fractures. *Indian journal of Orthopaedics.* 2003; 37:11-16
9. Low CK, Liao KH, Chew WY. Results of distal radial fractures treated by intra-focal pin fixation. *Ann* 2001; 30(6):573-6.
10. Imtiaz A, Hashmi, Sohail R, Syed SR. Modified Kapandji wiring technique for unstable fractures of distal end of radius. *Journal of Surgery Pakistan (International).* 2008;13 (2)
11. Casteleyn PP, Handelberg F, Haentjens P. Biodegradable rods versus Kirschner wire fixation of wrist fractures; a randomized trial. *J Bone Joint [Br].* 1992; 74(B):858-61.
12. Board T, Kocalkowski A, Andrew G. Does Kapandji wiring help in older patients? A retrospective comparative review of displaced intra-articular distal radial fractures in patients over 55 years. *Injury.* 1999 ;30(10):663-669
13. Rosenthal, Andrew H. , Chung, Kevin C. Intrafocal Pinning of Distal Radius Fractures: A Simplified Approach. *Annals of plastic surgery.* 2002;48(6):593-599
14. Shiota E. Intra-focal fixation for treating distal radius fracture: Results of 104 cases. *Journal of Orthopaedics Science.* 1998;4(2):106-114
15. Lenoble E, Dumontier C, Goutallier D, and Apoil A. Fracture of the distal radius. A prospective comparison between trans-styloid and Kapandji fixations. *J Bone Joint Surgery, Br.* 1995; 77(4): 562-567
16. Gravier R., Flecher X. , Parratte S., Rapaie P. , Argenson JN. Trans-styloid and intrafocal pinning of Pouteau-Colles fractures: Advantage in terms of post-operative stability compared with simple intrafocal pinning. *J Bone Joint Surg. Br.* 2005; 87B; 130-137