

CUBITUS VARUS IN YOUNG ADULTS CORRECTION WITH LATERAL CLOSING WEDGE OSTEOTOMY AND SCREW, K-WIRE AND SS-WIRE FIXATION

S Pandey, A Shrestha, AP Regmi, A Prajapati, S Dhakal and G Neupane

Department of Orthopedics, Chitwan School of Medical Sciences, Chitwan Medical College, Bharatpur.

Correspondence: Dr Suresh Pandey MS, Dept. of Orthopedics, Chitwan School of Medical Sciences, Chitwan Medical College Teaching Hospital, Bharatpur, e-mail: pandeys59@yahoo.com

ABSTRACT

Cubitus varus is common late complication due to childhood malunited supracondylar fracture. Treatment is indicated mainly for cosmetic reason as it rarely poses any problem with function. Correction in adult is challenging due to mature skeleton, high chance of stiffness, implant failure, late union or nonunion. There is different technique of osteotomy and fixation device in practice. We present our experience of correction of cubitus varus in young adult with lateral closing wedge osteotomy and fixation with screw, SS wire and supplemented with Cross K wires. It is a retrospective case analysis of 7 cases of cubitusvarus in young adult treated with lateral closing wedge osteotomy. Internal fixation was done with screw, figure of eight Stainless steel wire and supplemented with lateral and medial multiple K-wires. All cases were from 15 to 24 years of age (mean 19.4) with 3 female and 4 male. All had cubitusvarus ranging from 12- 25 deg (mean -17.14 deg) due to childhood malunited supracondylar fracture of humerus. Follow up duration was 3 -24 months (mean 13.5mth). All the osteotomy united clinically in mean duration of 9 weeks (range 8-12 weeks) with mean carrying angle 7 degree in postoperative phase. There was no loss of flexion and extension, no loss of fixation, no pin site infection, nonunion or neurovascular deficit. Lateral closing wedge corrective osteotomy and fixation with screw, SS wire and supplemented with additional K-wires is easy technique with satisfactory result in correction of cubitusvarus in young adults.

Keywords: cubitusvarus, lateral closing wedge osteotomy, K-wire

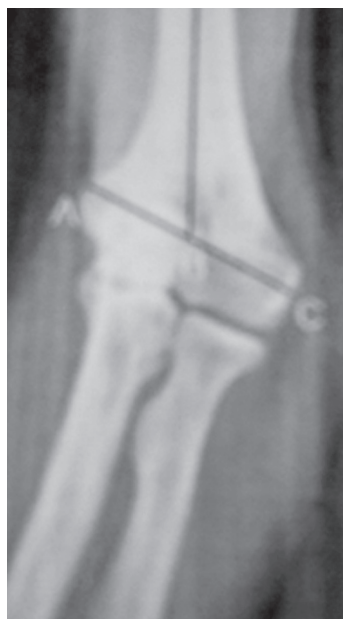INTRODUCTION

Cubitusvarus is the most common delayed complication after supracondylar fracture of humerus during childhood. Its incidence is higher upto 58% when managed conservatively with closed reduction and slab application.^{1,2} Medial tilt and medial rotation are the most important contributing factors for its development. With easy access and wide use of C-arm, closed reduction and percutaneous pinning is the treatment of choice in displaced fractures of supracondylar region of humerus in children. This allows better assessment and achievement of anatomical or near anatomical reduction intraoperatively hence by reducing the late complication of malunion. This deformity rarely poses any problem with function or range of motion. Most patients come for correction due to cosmetic reason. It is better corrected during childhood with different methods of corrective osteotomy. Correction of cubitusvarus in adult and fixation is challenging due to mature skeleton, inherent instability at osteotomy site, risk of delayed union and nonunion, implant failure, infection, stiffness and neurovascular complications. We hypothesize that this deformity can be corrected with simple lateral closing wedge osteotomy and fixation with screw, figure of eight wire and multiple K-wires to add stability with satisfactory result.

MATERIAL AND METHODS

This is a retrospective case analysis of the seven cases of cubitusvarus in adult treated in Chitwan Hospital pvt.Ltd. from duration of 2007 June to 2011 February. Old case sheets were collected from the record and data collected about the sociodemographic profiles, preoperative state of deformity, operative details and postoperative data. They were evaluated about the correction of deformity, range of motion, lateral condylar prominence after solid union. Preop Xray was taken for each patient with both the elbow in full extension and forearm in full supination parallel to each other anteroposterior film and lateral film of affected elbow. Pre operative Carrying angle (humeroradioulnar wrist angle) was measured as angle between the bisecting line of arm and forearm in both normal and affected side. Lateral prominence index was measured in both preoperative film and last follow up film as shown in figure below.

The lateral prominence index (%) was measured on the (A) preoperative and (B) postoperative radiographs using the formula, $(CB-AB)/AC \times 100$. It is usually negative in normal elbows Varus angle at the affected side and angle to be



corrected with lateral closing wedge osteotomy was calculated preoperatively.

SURGICAL TECHNIQUE

Under Brachial plexus block or general anesthesia with patient in supine position through lateral approach, distal humerus was exposed on lateral, anterior and posterior side subperiosteally at the supracondylar region leaving the medial periosteum intact. Osteotomy site and lateral wedge marked with scale and one drill hole above and one below the marked osteotomy site was made for screw placement converging medially and screw inserted. Then wedge of bone removed with the help of saw or drill leaving the medial cortex and periosteum intact. Osteotomy completed breaking the medial cortex and reduction done to correct the varus deformity and restoring the near normal carrying angle. Then SS wire used to fix the two screw in figure of 8 manner and to add the stability lateral² and medial one or one medial one lateral pins added from distal fragment to proximal fragment under C-arm control. Reduction and correction of deformity checked on C arm before closure. Long arm slab applied with elbow in 90 degree of flexion.

Wound inspection and dressing was done on 2nd and 4th postoperative day and case was discharged on 4th postoperative day. Suture was removed on 14th day and slab was converted to long arm cast for 4 more weeks. Range of motion exercise was started at 6 weeks of operation and follow up X ray done at 2, 6, 12 weeks. Pins were removed at 6 weeks and

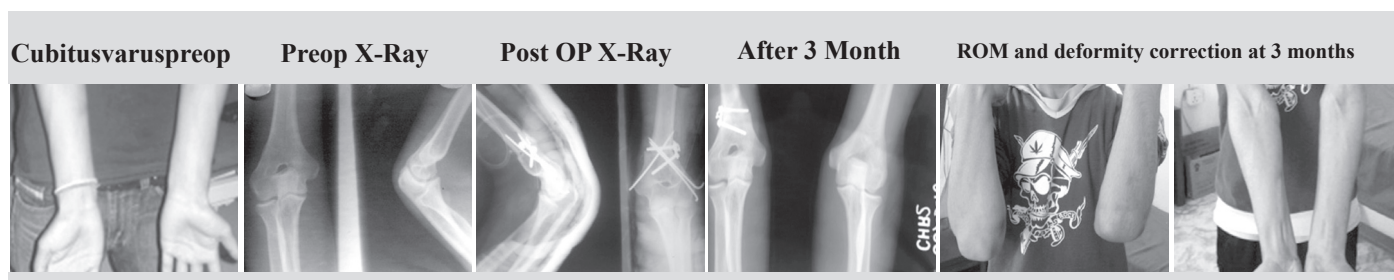
screw and SS-wire at 12 or weeks or later. Range of motion, union, carrying angle, lateral prominence index was measured at final follow up and result analysed.

RESULTS

There were total of 7 cases of young adult age ranging from 15-25 years (mean 19.4) with cubitus varus deformity of elbow ranging from 12-25 deg (mean 17.14). There were 4 male and 3 female with right hand in 4 cases. Follow up duration is from 3-26 months. All had developed deformity due to childhood malunited supracondylar fracture managed conservatively. All corrective osteotomy united clinically at 8-12 weeks (mean 9.14 weeks). There was no loss of motion preoperative and postoperative phase. Range of motion was equal to normal side. Flexion was 130-140 deg (mean 134.2) preoperatively and 130-140 deg (mean 133.5) at final follow up which is equal to normal side range of motion of 130-140 deg (mean 135). There was hyperextension of 5 deg in one case and 10 deg in one case which is not clinically significant. Mean lateral prominence index was 5.1 deg (Range 2.3- 7.5) preoperatively and improved to -11.5 deg (range -5 to -21.4) postoperatively. There was no case with loss of fixation, pin site infection, nonunion or any neurovascular complication. All were happy with the result as compared to preoperative state except one case complained with lateral condylar prominence.

Table 1: Patient data

Age	Sex	CA normal	Varus	CA post op	ROM prep op	ROM postop	ext	union time	Lat C Index preop	lat C index postop
18	M	10	15	7	130	130	0	8	4.5	-10.5
17	M	8	12	5	140	135	0	10	2.3	-12.6
18	F	10	15	10	140	140	5	10	5.2	-8.2
20	F	8	15	8	130	13	10	12	7	-5
24	M	8	20	8	130	135	0	8	3.6	-14.3
20	F	5	18	7	140	135	0	8	6	-9
15	M	6	25	7	130	130	0	8	7.5	-21.4



DISCUSSION

There are different corrective osteotomy techniques described like lateral closing wedge, medial open wedge, step cut translational osteotomy, dome osteotomy and pentalateral osteotomy in treating cubitusvarus deformity^{3,4}. There are different fixation techniques in practice like pins, screw, lateral plating posterior plating, each has got its own advantage and disadvantage. Correction in adult is different and difficult due to mature skeleton, increased instability at osteotomy site, delayed union and chance of stiffness⁵. In our study all cases had good correction of deformity with restoration of carrying angle to near normal. All united well with achievement of preoperative range of motion.

There are many studies showing different results of orrection of cubitusvarus in adult using different techniques of osteotomy and internal fixation.

Laupatterkasen et al in his study of Pentalateral osteotomy⁶ in 108 patients at the mean age of 14 years had shown satisfactory results, but information on patients older than 15 years was lacking. Matsushita et al had done Arc osteotomy⁷ in his study in three postpubertal patients with the mean age of 20 years, with pinning and 6 to 8 weeks of cast immobilization. In two of the three patients, total arc of motion decreased: in one patient by 40 deg and in the other by 10 deg. In a study of the dome osteotomy by Tien et al⁸, olecranon osteotomy was done for two postpubertal patients to apply the plate posteriorly, and these patients lost motion by 20 to 30 deg. In a study done by Chung et al operated with three-dimensional osteotomy³ for 23 adult patients, there was one nerve palsy associated with pinning and one myositis ossificans. In a step-cut osteotomy⁹ done by Kim et al the triceps muscle was divided to apply the Y-plate posteriorly. Although the triceps-splitting approach has been used safely for many elbow surgeries, peak triceps torque does not recover fully and the deficit is still 3% to 6% at 3 years and 6 months (3.5 years) after triceps division. We are doing study for correction of cubitusvarus deformity in adult with medial and lateral reconstruction plate after lateral closed wedge osteotomy through posterior triceps retracting approach in lateral position and early results are promising.

There are several limitation of our study. Since sample size is very less, we cannot compare our result with other techniques of correction and fixation studied by many authors. We started early motion at 6 weeks empirically despite no rigid fixation as compared to plating though it worked well in our case. We have not carried out preoperative and postoperative elbow score and statistical tools as sample size is very less.

CONCLUSION

In this small study we can say that Lateral closing wedge corrective osteotomy and fixation with screw, SS wire and supplemented with additional K-wires is easy technique yet satisfactory result in correction of cubitusvarus in young adults.

REFERENCES

1. Carlson CS, Rosman MA. Cubitusvarus: a new and simple technique for correction. *J PediatrOrthop* 1982;2:199–201.
2. Hoyer A. Treatment of supracondylar fracture of the humerus by skeletal traction in an abduction splint. *J Bone Joint Surg*. 1952;34:623–37.
3. Chung MS, Baek GH. Three-dimensional corrective osteotomy for cubitusvarus in adults. *J Shoulder Elbow Surg*. 2003;12:472–475
4. Uchida Y, Ogata K, Sugioka Y. A new threedimensional osteotomy for cubitusvarus deformity after supracondylar fracture of the humerus in children. *J PediatrOrthop*. 1991;11:327–331.
5. Hyun Sik Gong, Moon Sang Chung, Joo Han Oh, Hoyune Esther Cho, and Goo Hyun Baek. Oblique Closing Wedge Osteotomy and Lateral Plating for CubitusVarus in Adults. *ClinOrthopRelat Res*. 2008 April; 466(4): 899–906.
6. Laupattarakasem W, Mahaisavariya B, owsuwon W, Saengnipanthkul S. Pentalateral osteotomy for cubitusvarus: clinical experiences of a new technique. *J Bone Joint Surg Br*. 1989;71:667– 670.
7. Matsushita T, Nagano A. Arc osteotomy of the humerus to cor-rect cubitusvarus. *ClinOrthopRelat Res*. 1997;336:111–115.
8. Tien YC, Chih HW, Lin GT, Lin SY. Dome corrective osteotomy for cubitusvarus deformity. *ClinOrthopRelat Res*. 2000;380:158–166.
9. Kim HT, Lee JS, Yoo CI. Management of cubitusvarus and valgus. *J Bone Joint Surg Am*. 2005;87:771–780.